



Food and Agriculture
Organization of the
United Nations

eofmd
european commission for the
control of foot-and-mouth disease

FOOT-AND- MOUTH DISEASE

PRACTICAL GUIDELINES FOR HUNTERS

What is Foot-and-Mouth Disease?

Foot-and-Mouth Disease (FMD) is a highly contagious viral disease in domestic and wild cloven-hoof animals. It can profoundly affect husbandry and wildlife management and conservation by evolving into severe epidemics which reduce productivity of susceptible animals.

FMD is certainly one of the most significant animal diseases in terms of international trade.

Susceptible wildlife

FMD affects all wild cloven-hoof animals. The susceptible European wildlife with high importance include wild boar (*Sus scrofa*), roe deer (*Capreolus capreolus*), red deer (*Cervus elaphus*), fallow deer (*Dama dama*), mouflons (*Ovis orientalis*) and others.

What to do with the carcass of FMD susceptible wild animals?

When hunting in an area under restrictions due to FMD, any carcass of FMD susceptible game should not be opened and cut on the ground immediately after the game is hunted. It should be taken to the nearest game collection center. The carcass should be transported in a plastic bag or other biosecure ways to avoid potential contamination of the environment with possibly infected material.

In the game collection center, the carcass should be identified with an individual number. The following data should be recorded for every animal:

- Date and time of entrance of the carcass in the collection center
- Area/ geographical coordinates where the animal was hunted
- Name of the concerned hunter/hunting club
- Type, sex, age, weight of the hunted animal (or game)
- Visible lesions (if any).

The internal organs should be removed and kept separately in the game collection center with the same identification number as the carcass. Samples should be collected and sent to the laboratory for testing. Should the results be negative, meat and other products fit for human consumption should be returned to hunter. However, if a positive carcass was detected in game collection center, all carcasses stored at same time should be destroyed, in order to avoid possible direct or indirect contamination.

What samples should be taken for FMD testing?

Samples should be taken after instruction from the competent veterinary authority.

Appropriate samples are blood, all kind of vesicles and their fluid as well as tonsils. Samples should be identified and properly packaged (crucial to avoid any contamination of the environment during transportation to laboratory).

How to recognize FMD in wildlife

FMD is characterized by:

- weakness, fatigue,
- acute lameness in a number of animals,
- salivation,
- vesicles (fluid-filled blisters),
- lesions in the mouth, on the feet (figures 3 and 4), and/or the teats that can be seen in the early stages of the disease.

Most often diseased animals show lameness on all feet but this is difficult to recognize during the chasing and hunting of animals. It also happens that animals do not show any signs of disease but they can shed the virus, become “carriers” and remain a source of infection for other wild and domestic susceptible animals. Regardless of the signs observed, the diagnosis should be confirmed by a laboratory.

In wild boar, lesions begin with a vesicle on the dorsum of the snout (figure 1) and the interdigital space between the hoofs (figure 2). Over the next days, several ruptured vesicles in the interdigital space, the coronary band, the digits, the heel, claws and the lips with serofibrinous in-filling are detectable. Post infection healing and claw deformation is visible (figure 5).

What is the danger of handling hunted animals affected by FMD?

Improper handling and storage of a carcass and offal of hunted cloven-hoof game may lead to spread and source of infection for other wild animals and domestic livestock (cattle, sheep and goats, pigs). Animals can be affected by contact with blood (left from cutting, skinning of animals on the open ground), infected game products, skins, internal organs etc. Game meat products that did not undergo heat treatment are especially dangerous. All skins and internal organs not fit for human consumption should be disposed of by burial or burning. Hygiene and biosecurity during hunting is a vital issue.

Fig. 1. Vesicle on the dorsum of the snout of a wild boar (© FLI)

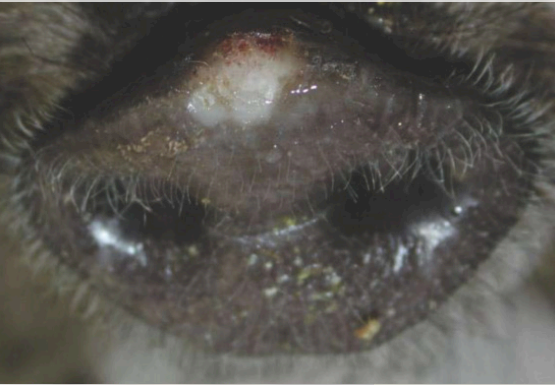


Fig. 2. Vesicle in the interdigital hoof space of a wild boar (© FLI)

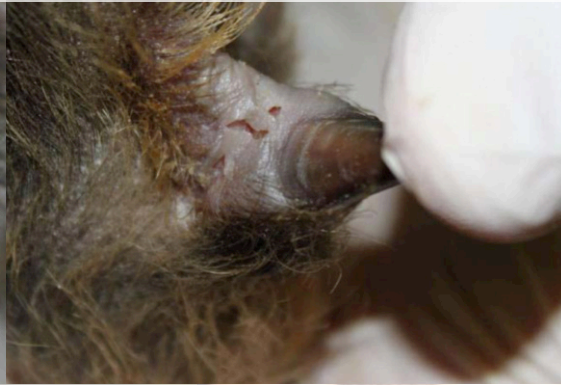

Fig. 3. FMD lesion on the hoof of a wild boar (© FLI)

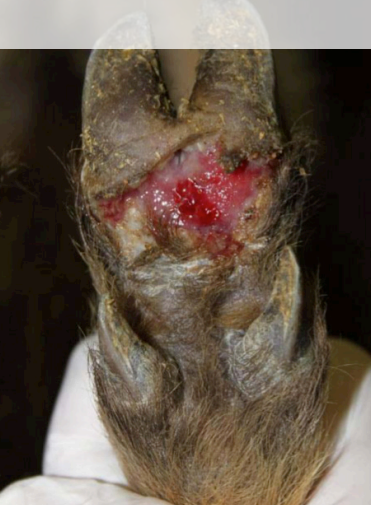

Fig. 4. FMD lesion on the hoof of a wild boar (© FLI)

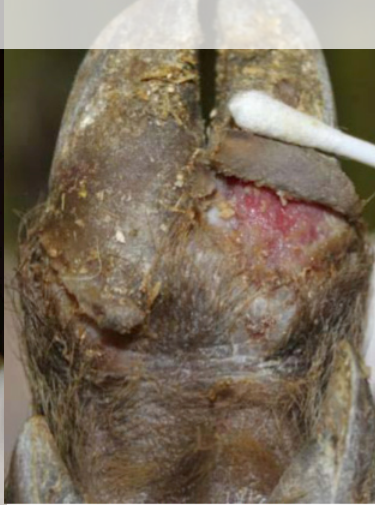
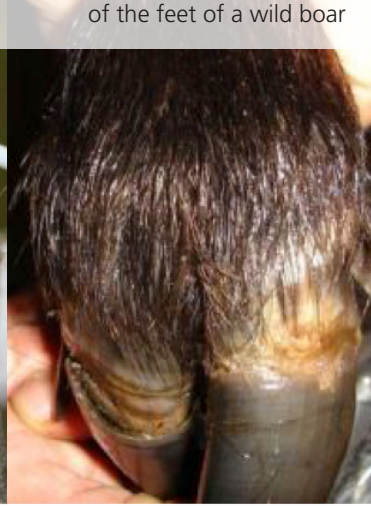
Fig. 5. Post infection healing and claw deformation of the feet of a wild boar



Help us stop transmission of the disease and report immediately to a veterinarian if you recognize any of these lesions.



Funded by the European Union

Eufmd@fao.org
fao.eufmd.org



Thinking of the environmental footprint



Some rights reserved. This work is available under a CC BY-NC-SA 3.0 IGO licence